

Micronutrient Malnutrition – Detection, Measurement and Intervention: A Training Package for Field Staff

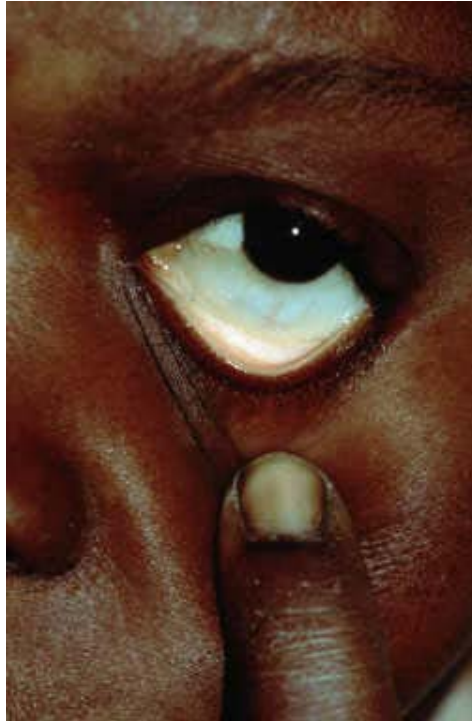Compiled by the
Institute of Child Health
For UNHCR

Photo-cards for Printing



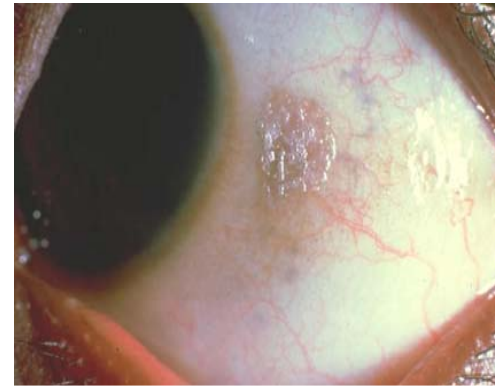
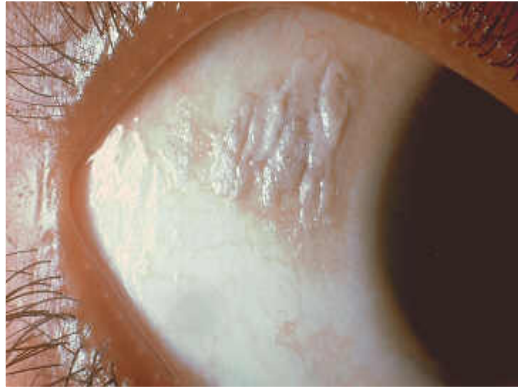Version 1 2003

Iron Deficiency Anaemia

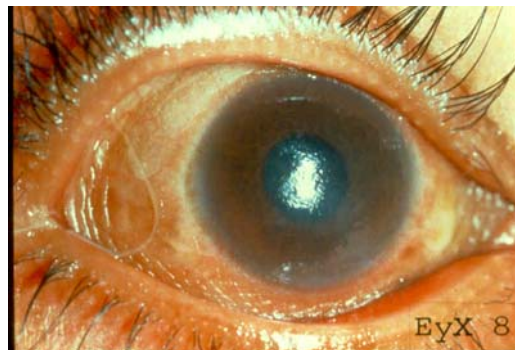

Pale mucous membranes in the eye and the tongue are signs of anaemia. You may see these signs in males and females of all ages.

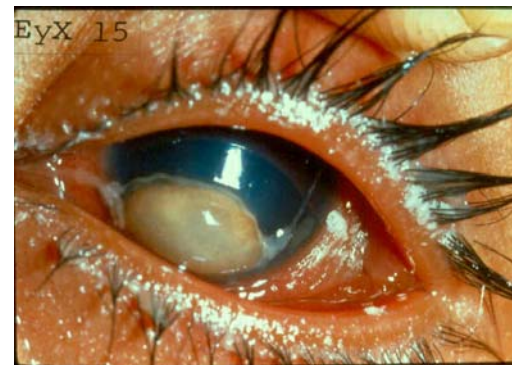
Vitamin A Deficiency – Xerophthalmia



Bitots spots (X1B) are foamy white areas on the white of the eye. Be careful not to confuse them with other types of eye problems. These signs will most often be seen in children.

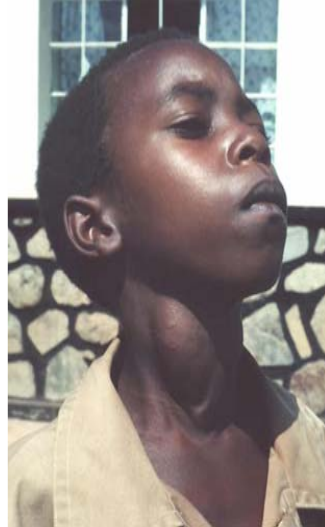

Corneal Xerosis(X2)



Keratomalacia (X3)

Iodine Deficiency – Goiter examination

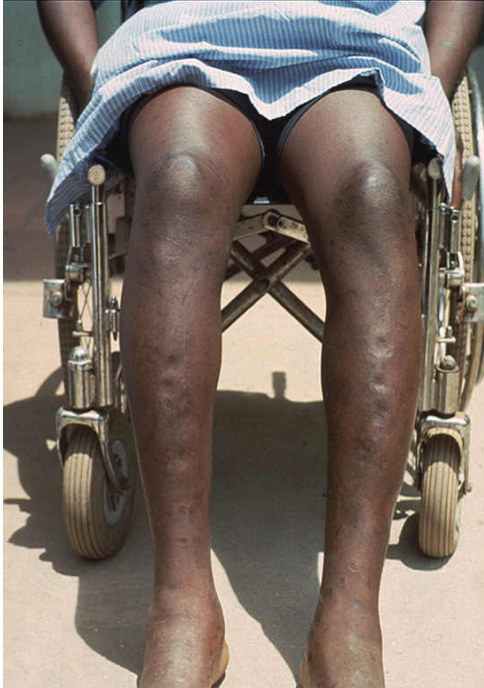

Goitre can be examined by looking or by feeling the neck (palpating). If the goiter is not large it may only be seen if the head is tilted gently backwards. The visible goitres seen in the 2 pictures on the top left are Grade 2.



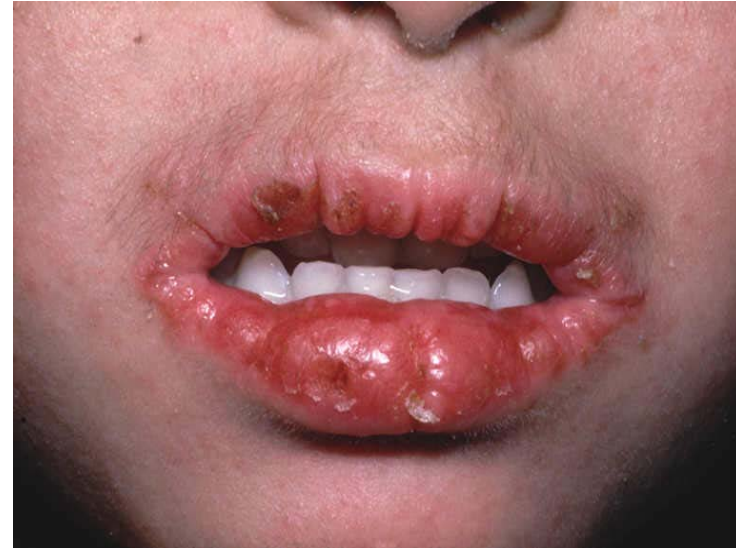Iodine deficiency can also cause developmental problems in children such as cretinism

Thiamine Deficiency - Beriberi



Oedema is seen in the wet form of beriberi. However, it is also caused by general malnutrition and can be seen in children and adults.

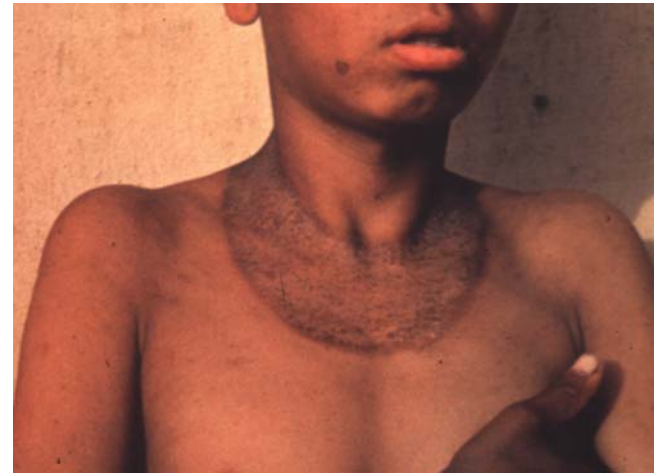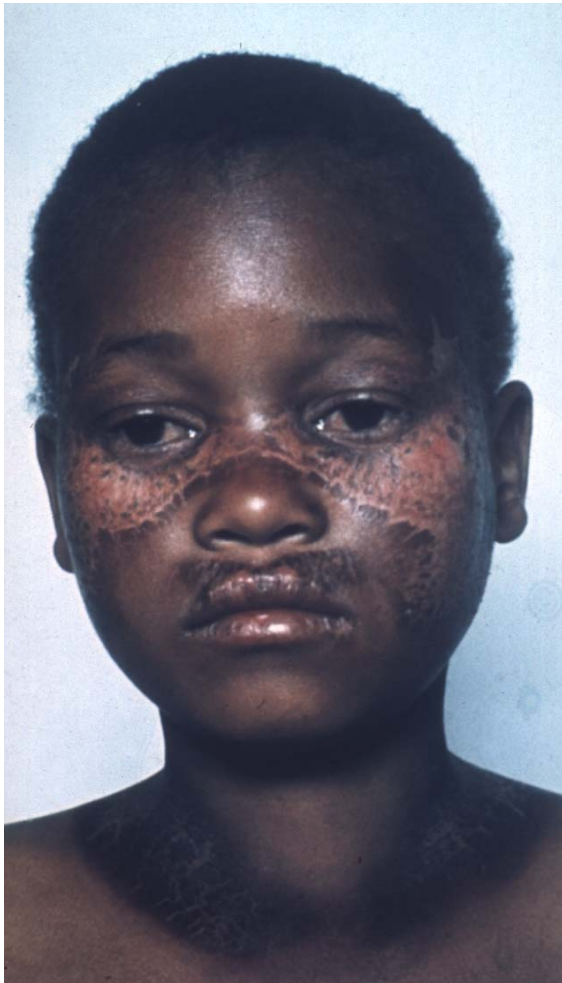Riboflavin Deficiency - Ariboflavinosis



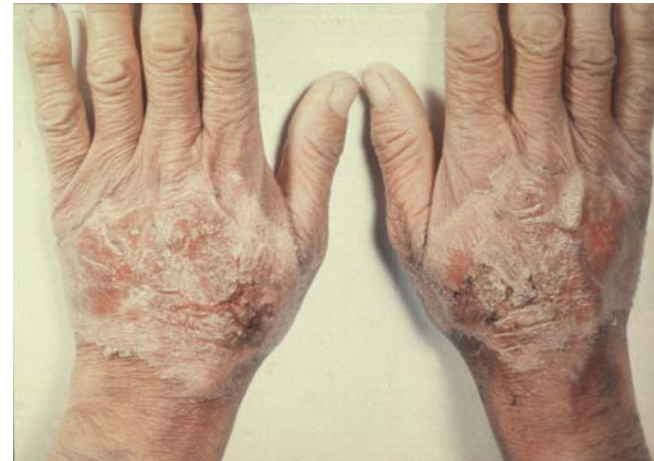Lesions of the mouth are seen in riboflavin deficiency. They are called *angular stomatitis* if the fissures are at the corners of the mouth and *cheilosis* if they are elsewhere on the lips.

Niacin Deficiency - Pellagra

Butterfly
sign



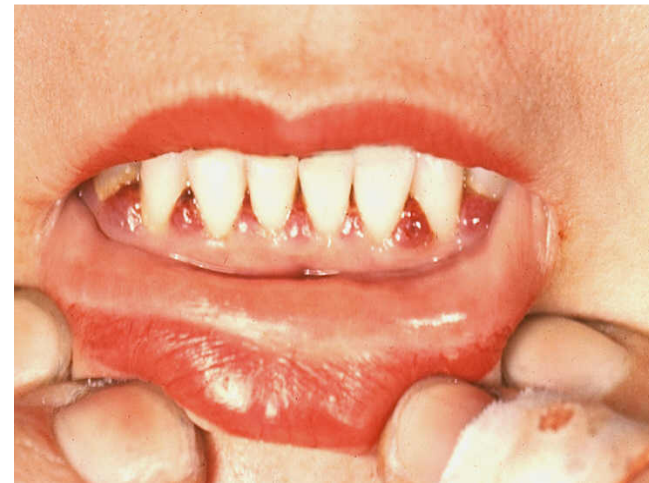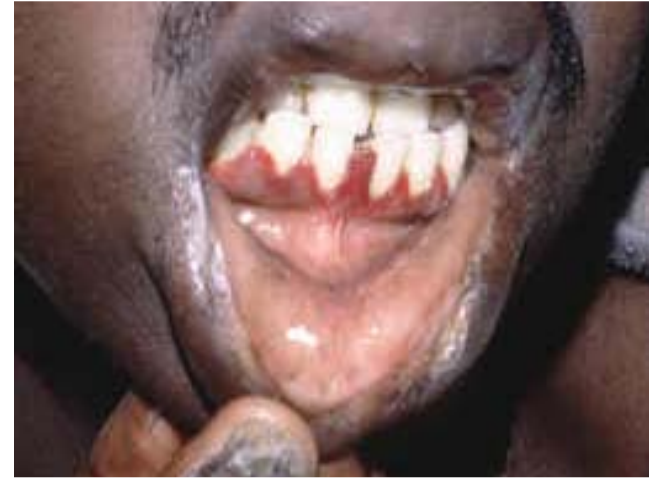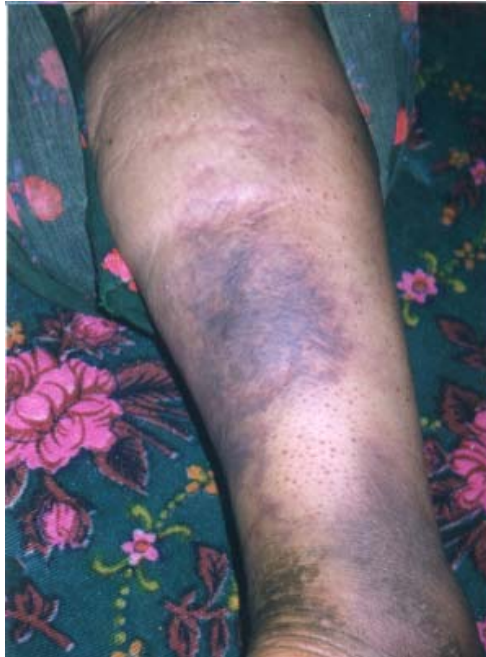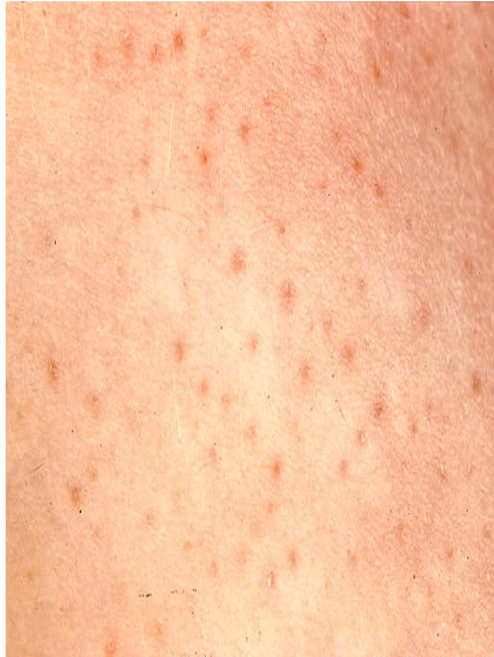Casal's
collar



A rash (dermatitis) which is on both sides of the body, and on skin normally exposed to sunlight is a sign of pellagra.

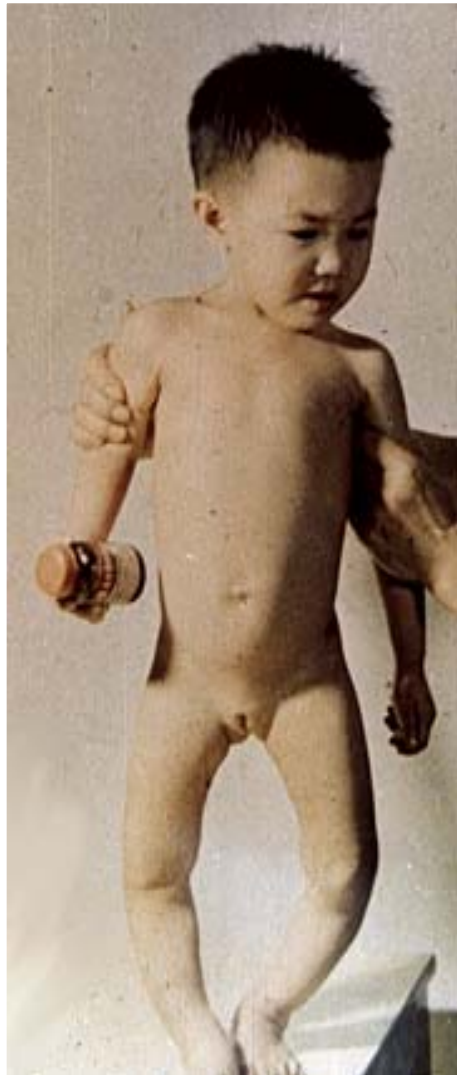Check the face, neck, hands, arms and legs.

Vitamin C Deficiency - Scurvy

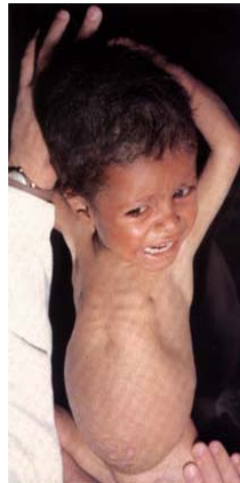

Bleeding around the bases of the hair on the legs (Perifollicular hemorrhage) and the gums in between the teeth are signs of scurvy. There may be areas of bruising as seen in second picture. There may also be swelling of the bone joints.

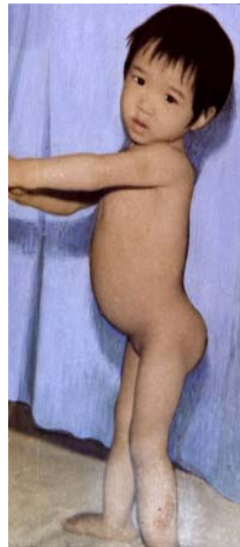Vitamin D deficiency - Rickets



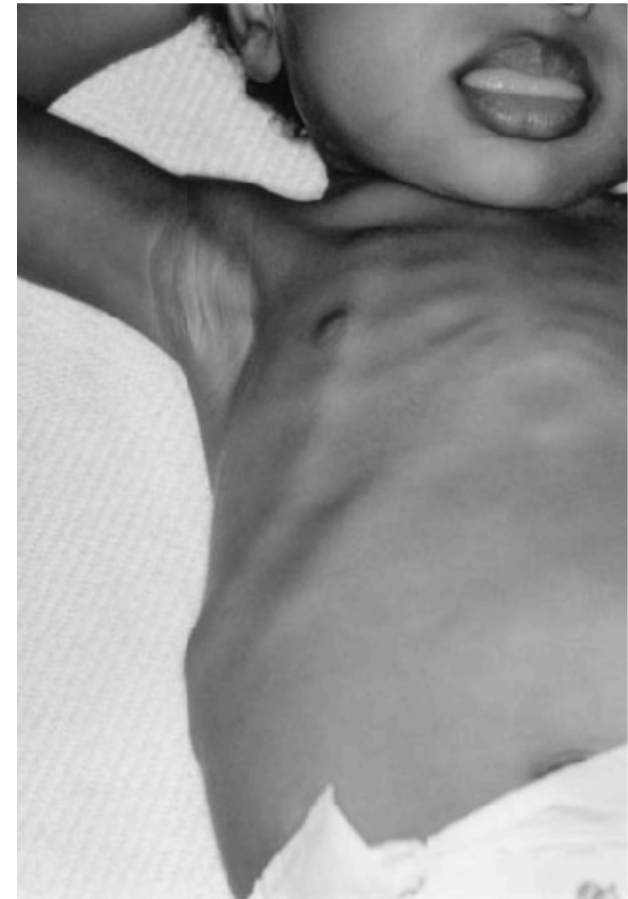Bow legs



Harrison's Groove or Pigeon Chest



Spinal deformity



**Beading of the rib cage
(rachitic rosary)**